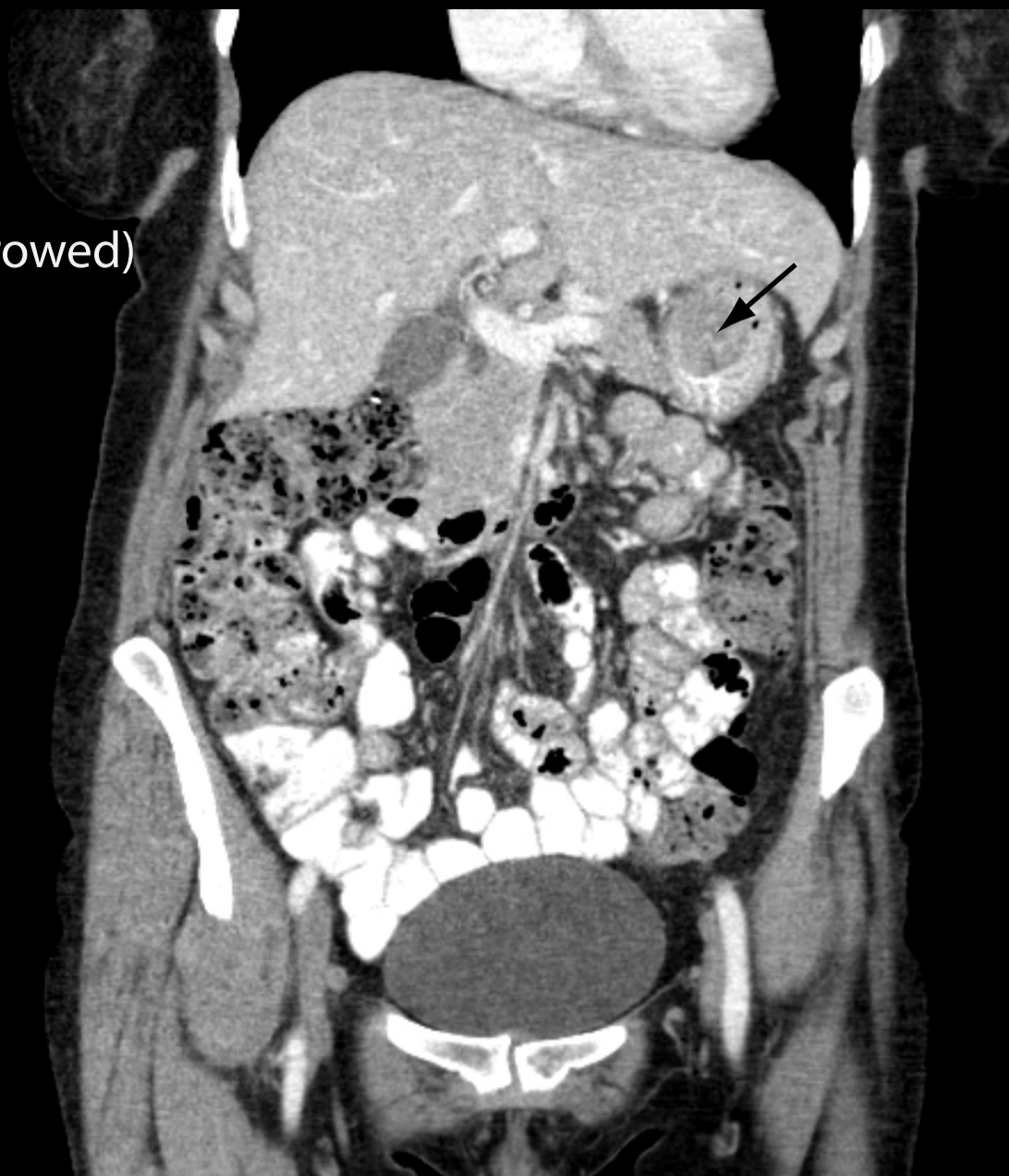


Gastric GIST

Coronal CT showing gastric GIST (arrowed)



Axial CT and CT PET images of the same patient. Note the uptake by the GIST on the PET; the kidneys also show tracer in the collecting system

